

BASIC SCIENCE STUDIES

Selective Pressure-Regulated Retroinfusion of Fibroblast Growth Factor-2 Into the Coronary Vein Enhances Regional Myocardial Blood Flow and Function in Pigs With Chronic Myocardial Ischemia

Georges von Degenfeld, MD,* Philip Raake, MD,* Christian Kupatt, MD,* Corinna Lebherz, MD,* Rabea Hinkel,* Franz Josef Gildehaus, PhD,† Wolfgang Münzing, PhD,† Andrea Kranz, PhD,‡ Johannes Waltenberger, MD,‡ Marcus Simoes, MD,§ Markus Schwaiger, MD,§ Eckart Thein, MD,|| Peter Boekstegers, MD*

Munich and Ulm, Germany

OBJECTIVES	We sought to improve regional myocardial delivery and subsequent collateral perfusion induced by basic fibroblast growth factor-2 (FGF-2) using selective pressure-regulated retroinfusion of coronary veins for delivery. This hypothesis was tested in a newly developed pig model with percutaneous induction of chronic ischemia.
BACKGROUND	Selective pressure-regulated retroinfusion of coronary veins is a catheter-based procedure that has been shown to provide effective regional delivery of drugs and gene vectors into ischemic myocardium.
METHODS	A high-grade stenosis with subsequent progression to total occlusion within 28 days was induced by implanting a reduction stent graft into the left anterior descending artery (LAD). After seven days, a 30-min retroinfusion (anterior cardiac vein) was performed with ($n = 7$) or without ($n = 7$) 150 μg FGF-2 and compared with a 30-min antegrade infusion of 150 μg FGF-2 into the LAD ($n = 7$). Sonomicrometry to assess regional myocardial function at rest and during pacing, and microspheres to assess regional myocardial blood flow, were performed 28 days after implantation of the reduction stent.
RESULTS	Retroinfusion of FGF-2 compared favorably with controls and with antegrade infusion of FGF-2 with regard to regional myocardial function at rest ($18.5 \pm 4.1\%$ vs. $5.7 \pm 2.9\%$ vs. $7.9 \pm 1.8\%$, respectively, $p < 0.05$) and during pacing. Regional myocardial blood flow was also higher in the LAD territory after retroinfusion of FGF-2 (1.07 ± 0.14 vs. 0.66 ± 0.07 vs. 0.72 ± 0.17 $\text{ml}\cdot\text{min}^{-1}\cdot\text{g}^{-1}$, $p < 0.05$).
CONCLUSIONS	Selective pressure-regulated retroinfusion increased tissue binding of FGF-2 and enhanced functionally relevant collateral perfusion compared with antegrade intracoronary delivery in pigs with chronic myocardial ischemia. (J Am Coll Cardiol 2003;42:1120–8) © 2003 by the American College of Cardiology Foundation

Angiogenic growth factors such as basic fibroblast growth factor (FGF-2) and vascular endothelial growth factor (VEGF) have been shown to induce collateral growth in myocardial ischemia (1). Growth factors have been applied

See page 1129

by injection into the myocardium (2) or by infusion into the coronary artery (3–7). With regard to FGF-2, repeated intracoronary bolus administration on two days was neces-

sary to improve myocardial perfusion by 31% in dogs (3). In a pig model of chronic myocardial ischemia, a 6- $\mu\text{g}/\text{kg}$ FGF-2 but not a 2- $\mu\text{g}/\text{kg}$ FGF-2 single intracoronary treatment improved collateralization and regional myocardial function (4), suggesting a dose-dependent effect of FGF-2. Although antegrade administration of angiogenic proteins has been promising in the ameroid constrictor pig model (4), recent placebo-controlled clinical studies using intracoronary delivery of recombinant VEGF-A₁₆₅ or FGF-2 showed only weak evidence for efficiency (8–10). The short interval of time after intracoronary injection, leading to limited tissue binding of the growth factor, may result in inadequate local delivery of the angiogenic growth factors to the ischemic myocardium (10).

In this study, we sought to increase the interval of time and thereby enhance tissue binding of recombinant angiogenic proteins by delivery into the coronary vein using catheter-based selective pressure-regulated retroinfusion (11). It has been shown previously that selective pressure-

From *Internal Medicine I, Grosshadern and †Nuclear Medicine, Grosshadern University Hospital, Munich, Germany; ‡Internal Medicine II, University Hospital, Ulm, Germany; the §Institute of Nuclear Medicine, Klinikum rechts der Isar, Munich, Germany; and the ||Institute of Surgical Research, Munich, Germany. This research was supported by the Deutsche Forschungsgemeinschaft (Bo 991/4-1 and 991/4-2 and in part by DO688/1-1 and SFB451/B1). Dr. von Degenfeld and Philip Raake contributed equally to this manuscript. Current address for Dr. von Degenfeld: Baxter Laboratory in Genetic Pharmacology, Stanford University School of Medicine, Stanford, California.

Manuscript received August 13, 2002; revised manuscript received April 14, 2003, accepted April 17, 2003.

Abbreviations and Acronyms

CX	= circumflex artery
FDG	= fluorodeoxyglucose
FGF-2	= fibroblast growth factor-2
LAD	= left anterior descending artery
LV	= left ventricle/ventricular
MI	= myocardial infarction
PET	= positron emission tomography
VEGF	= vascular endothelial growth factor

regulated retroinfusion results in highly efficient and regional targeting of drugs and reporter genes to ischemic myocardium (12-14). Hence, the aim of the present study was to investigate whether selective pressure-regulated retroinfusion of recombinant FGF-2 into coronary veins induces functionally relevant collateral perfusion, and to compare this delivery method with antegrade delivery into the coronary artery.

METHODS

The investigation followed the "Guide for the Care and Use of Laboratory Animals" (NIH Publication No.85-23, revised 1985) and was approved by the Bavarian Animal Care- and Use-Committee (AZ 2511-106/99).

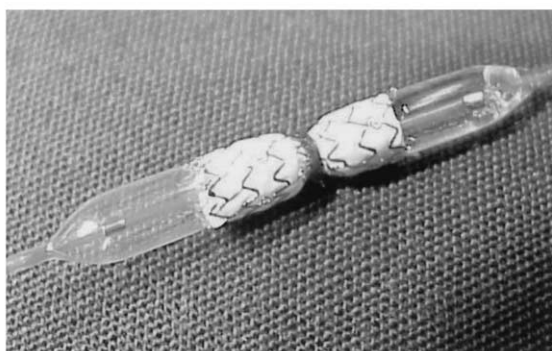
The study was carried out in 52 German farm pigs (28 ± 3 kg). Seven pigs were used to establish the reduction-stent model; six pigs were used for binding experiments at day seven; 21 pigs were used for assessment of therapeutic angiogenesis at day 28 after three different treatment protocols at day seven (groups A, B, C). Of the remaining 18 pigs, 11 pigs died before reaching day seven, and five pigs were excluded because of complete occlusion of the reduction stent at day seven. Another two pigs (1 of group A, 1 of group C) died before reaching day 28 and were also excluded from analysis.

All pigs were premedicated with clopidogrel (300 mg) and aspirin (300 mg). Anesthesia was induced by intramuscular ketamine (500 mg) and azaperone (10 mg/kg) and maintained by midazolam IV, piritramide IV, and inhaled Enflurane 0.5% to 2.0%. Pigs were mechanically ventilated. A catheter introducer-sheath was placed into the carotid artery, and heparin 20,000 IU IV was injected.

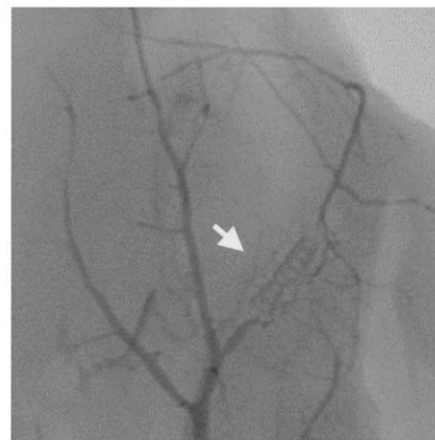Induction of chronic myocardial ischemia by implantation of a reduction stent into the left anterior descending artery (LAD). A coronary polytetrafluoroethylene-covered stent-graft (Jomed, Germany) of 13 mm length was placed on a 1.5 mm diameter needle, and a ligature was placed around the middle of the stent (Fig. 1A). Thereafter, the stent was crimped on a percutaneous transluminal



A



B



C

Figure 1. Induction of chronic myocardial ischemia using a reduction stent. (A) A stent graft is ligated in the center. (B) The stent is crimped on balloon and inflated at 14 atm; it remains unexpanded at the site of the ligature, resulting in an hourglass-shaped stenosis. (C) Postmortem angiogram at day 28. The **arrow** indicates the location of the reduction stent, which is totally occluded. Collaterals are visible connecting the proximal left anterior descending artery (LAD) and diagonal branches to the distal LAD.

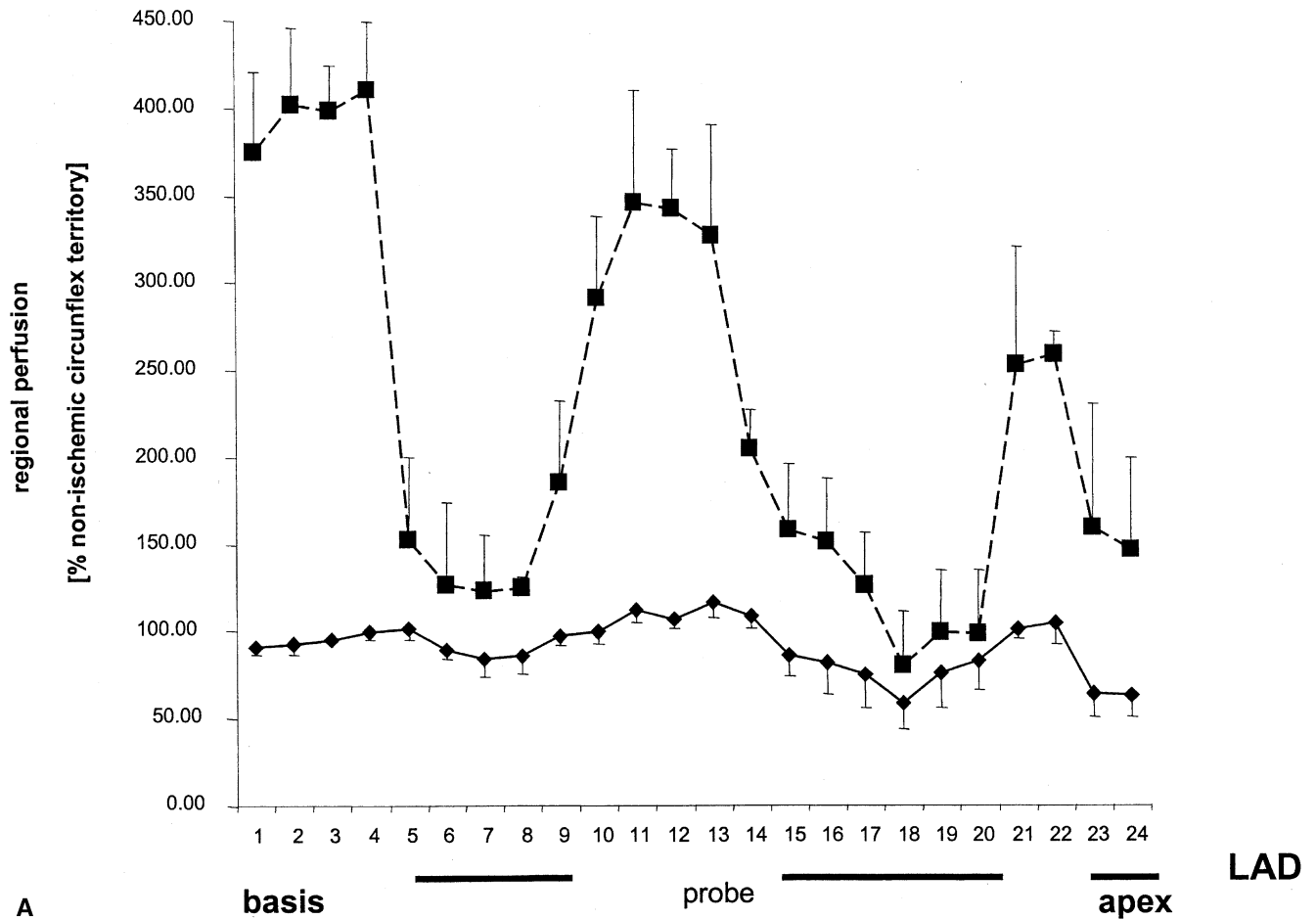


Figure 2. Regional perfusion map of the left ventricular after slicing from the basis to the apex. (A) Seven days after implantation (n = 7). **Diamond line** = rest; **square line** = adenosine. *Continued on next page.*

angioplasty-balloon (20 mm length/3.0 mm diameter) (Fig. 1B) and implanted (14 atm) into the proximal LAD in all 52 pigs. The stent remained unexpanded at the site of the ligature, resulting in an hourglass-shaped stenosis (Fig. 1B). The degree of stenosis calculated from the cross-sectional area at the site of the ligature (1.8 mm²) and at the expanded edges of the stent (7.1 mm²) was 75%. An antiplatelet and anticoagulation regimen consisting of clopidogrel 75 mg PO, ASA 100 mg PO, and rivaroxan 0.25 ml SC was administered daily for 28 days.

After seven days, the degree of LAD stenosis at the site of the stent was reexamined (fluoroscopy). If the stent was occluded, pigs were excluded from further analysis (n = 5). In all other pigs, hemodynamics and left ventricular (LV) function (LV end-systolic and end-diastolic pressures, dp/dt_{max}, dp/dt_{min}) were measured using a microtip catheter (Millar). Cardiac output was determined by thermodilution.

Application of FGF-2. Seven days after implantation of the reduction stent and after fluoroscopic control of the patency of the stent, pigs were treated by retroinfusion of saline (controls, group A, n = 7) or 150 μg FGF-2 (retroinfusion, group B, n = 7). In group C (n = 7), pigs

were treated with antegrade intracoronary infusion of 150 μg FGF-2 into the LAD.

In groups A and B, a 6F 4-lumen retroinfusion catheter was selectively placed into the anterior cardiac vein (12–14). Pressure-regulated retroinfusion of arterial blood without suction was carried out for 30 min with a preset retroinfusion pressure of about 20 mm Hg higher than the systolic coronary venous occlusion pressure, resulting in a mean retroinfusion pressure of 58 ± 9 mm Hg. Heparinized saline solution containing 150 μg FGF-2 (Peprotech, Germany) was continuously added to the retroinfused arterial blood throughout the 30-min treatment period in group B, whereas heparinized saline solution alone was added in the controls (group A). In group C, heparinized saline solution containing 150 μg FGF-2 was continuously infused during 30 min into the LAD proximal to the reduction stent.

In six additional experiments, the binding of ¹²⁵I-labeled FGF-2 was studied to compare antegrade and retrograde application. Fibroblast growth factor-2 was radiolabeled using the chloramine T-catalyzed iodination method similar to that previously described in detail (15). Specific radioactivity of the iodinated FGF-2 was 11 μCi/

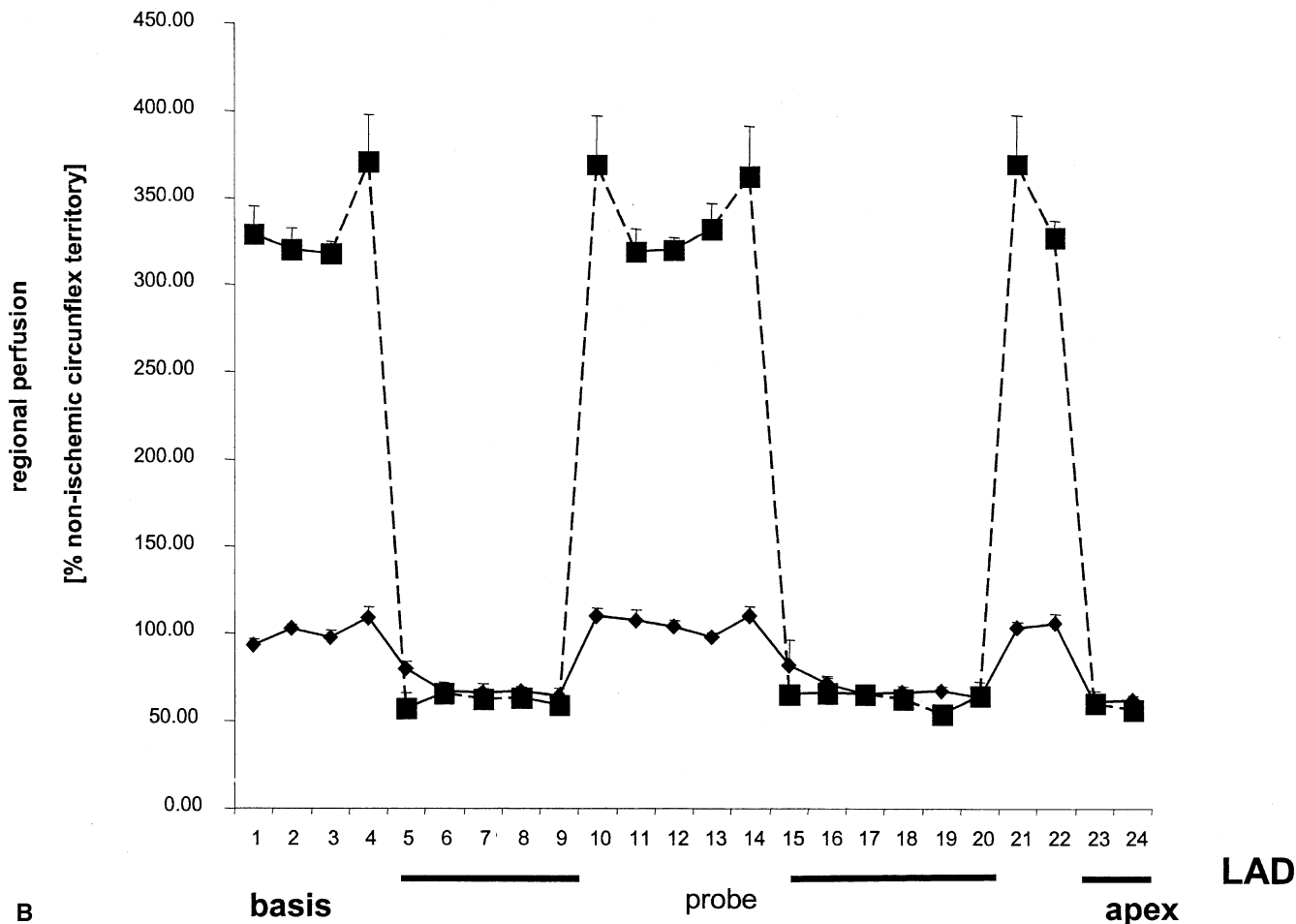


Figure 2 Continued. (B) Twenty-eight days after implantation (n = 7). **Diamond line** = rest; **square line** = adenosine. Adenosine = regional myocardial perfusion determined after intracoronary adenosine; LAD = left anterior descending artery; probe = number of transmural probes; rest = regional myocardial perfusion at rest.

μg . [^{125}I]Fibroblast growth factor-2 retained full biological activity in a proliferation assay (data not shown). In six pigs with similar high-grade stenosis seven days after implantation of the reduction stent, 30 μg [^{125}I]FGF-2 and 120 μg unlabeled FGF-2 were applied during 30 min, either by antegrade infusion (LAD) or by pressure-regulated retroinfusion (anterior cardiac vein). Forty-five minutes after application, the pigs were euthanized, and transmural samples from the targeted LAD territory and the nontargeted circumflex artery (CX) territory and different organs were harvested and measured using a γ -counter (LKB, Sweden). **Regional myocardial blood flow.** Regional myocardial blood flow was measured using fluorescent labeled microspheres (16). Briefly, 1×10^7 microspheres were injected into the left atrium (Molecular-Probes) for each measurement. Reference blood samples were withdrawn from the abdominal aorta at a rate of 4.1 ml/min.

In seven pigs used to establish the reduction-stent model, regional myocardial blood flow was studied at rest and during adenosine-induced flow reserve ($80 \mu\text{g}\cdot\text{kg}^{-1}\cdot\text{min}^{-1}$ intracoronary) using different colors of microspheres seven and 28 days after implantation of the reduction-stent graft.

Regional myocardial blood flow at rest and during pacing (110 beats/min) was determined at day 28 after implantation of the reduction stent in groups A, B, and C. In all pigs, two transmural myocardial samples were obtained from the proximal and distal ischemic LAD territory and one sample from the CX territory after euthanasia. Samples were divided into endocardial, midmyocardial, and epicardial probes. Fluorescence was measured using a sample processing unit (16).

Regional myocardial function. Subendocardial segment shortening was determined by sonomicrometry (HSE, Germany) (17). After sternotomy, three pairs of 5-MHz ultrasonic crystals were implanted in two defined areas of the ischemic LAD territory (1 cm and 3 cm distal to the reduction stent) and in the CX territory.

Capillary density. The central slice of each transmural myocardial probe was used for assessment of capillary density. Alkaline phosphatase staining was performed (18) and separately analyzed by two investigators blinded to the groups.

Collateral score. An in vivo angiogram was performed prior to thoracotomy (Exposcop 8000, Ziem, Germany). For assessment of collateral arteries, a postmortem angiogram was obtained (Coroskop HIP, Siemens, Germany) by

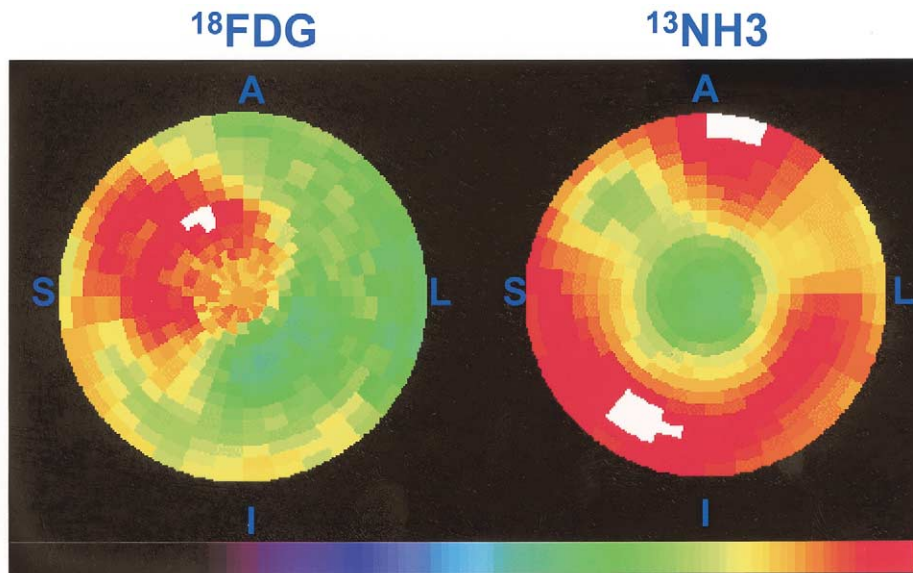


Figure 3. Polar map display of relative myocardial uptake of ^{18}F fluorodeoxyglucose (^{18}FDG) and ^{13}N -labeled ammonia ($^{13}\text{NH}_3$). The most basal LV wall segments are depicted in the most peripheral rings, whereas the most apical occupies the center of the map. S = septum; I = inferior; L = lateral; A = anterior. Segments with brighter colors (white, red) present higher uptake values. There is a large $^{13}\text{NH}_3$ uptake defect in left anterior descending artery territory corresponding to 20% of the left ventricular. In the same area, increased uptake of ^{18}FDG is observed.

flushing the coronaries of the excised heart with saline and 0.2 mg glyceryl-trinitrate, followed by injection of 10 ml contrast agent into the left coronary artery (100 mm Hg). In the postmortem angiogram, collateral arteries connecting the CX, the proximal LAD, or the first diagonal branch with the distal LAD were counted by two separate investigators blinded for the groups (19).

Assessment of infarct size and viability. In seven pigs used to establish the reduction-stent model, infarct size was determined at 28 days by tetrazolium-chloride staining followed by slicing of the LV (14) using computer based planimetry (SigmaScan-Pro). In groups A, B, and C myocardial infarction (MI) was determined at day 28 by morphometric assessment and by histology after standardized sampling of nine representative transmural probes (0.5 cm in diameter) of the entire LAD territory (1 cm, 2 cm, and 3 cm distal to the reduction stent as well as 0.5 cm, 1.5 cm, and 2.5 cm perpendicular to the LAD). Each sample was cut on a microtome (15 μm sections; hemalaun-eosine staining) and assessed for the presence of MI.

Fluorodeoxyglucose (FDG)-positron emission tomography (PET). Dynamic PET was performed in three pigs of the control group using a whole-body scanner (CTI/ECAT 951R/31; Siemens, Germany). Twenty mCi of ^{13}N -labeled ammonia ($^{13}\text{NH}_3$) were administered intravenously (30 s). Dynamic PET acquisition was performed using varying frame durations (12 \times 10 s, 6 \times 30 s, and 3 \times 300 s). Thirty minutes later 10 mCi of ^{18}FDG were injected and dynamic image acquisition was repeated. A threshold of <50% of the maximum pixel count density was used for defining areas with significant reduction in $^{13}\text{NH}_3$ uptake (perfusion defect). Further processing and analysis comprised myocardial rate of glucose uptake in ^{18}FDG study.

Statistical analysis. All data were analyzed using SPSS. Data are presented as mean \pm standard error of the mean (SEM). The investigators performing the experiments at day 28 were blinded for the assigned treatment groups at day seven. Differences between groups A, B, and C were assessed with ANOVA. In case of statistically significant differences with ANOVA, two group comparisons were

Table 1. Hemodynamics

	Group A		Group B		Group C	
	Day 7	Day 28	Day 7	Day 28	Day 7	Day 28
Heart rate [beats/min]	73.3 \pm 0.9	79.0 \pm 2.8	74.0 \pm 10.0	74.0 \pm 3.5	74.8 \pm 1.8	76.3 \pm 3.1
LVPsys [mm Hg]	74.0 \pm 2.5	80.8 \pm 9.2	77.0 \pm 15.4	78.0 \pm 2.8	77.2 \pm 4.5	79.1 \pm 3.3
LVEDP [mm Hg]	10.7 \pm 3.8	16.5 \pm 2.1*	9.5 \pm 5.2	10.8 \pm 1.6	10.2 \pm 3.2	14.3 \pm 1.5
Cardiac output [l/min]	2.6 \pm 0.5	3.4 \pm 0.4	2.4 \pm 0.4	3.3 \pm 0.2	2.5 \pm 0.3	3.3 \pm 0.4
dP/dtmax [mm Hg/s ²]	886 \pm 123	861 \pm 81	957 \pm 245	1115 \pm 371	902 \pm 81	921 \pm 110
dP/dtmin [mm Hg/s ²]	-1036 \pm 99	-870 \pm 306	-1029 \pm 111	-963 \pm 125	-1010 \pm 98	-880 \pm 156

*p < 0.05 group A vs group C at day 28. Group A = controls; group B = pigs treated by retroinfusion of fibroblast growth factor-2; group C = antegrade infusion of fibroblast growth factor-2. Measurements were carried out 7 and 28 days after implantation of the reduction-stent.

dP/dtmax = peak velocity of left ventricular pressure rise; dP/dtmin = peak velocity of left ventricular pressure fall; LVEDP = left ventricular end diastolic pressure; LVPsys = systolic left ventricular pressure.

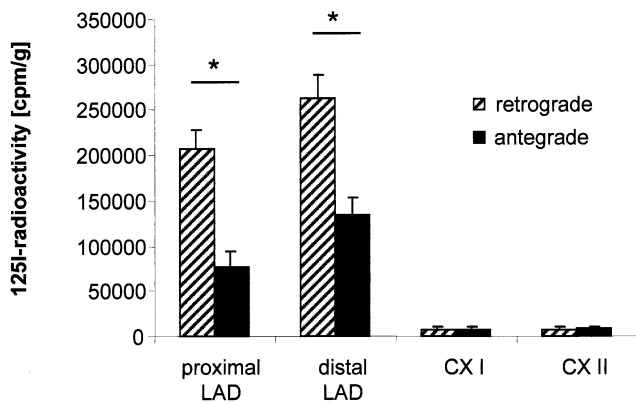


Figure 4. Tissue binding of ¹²⁵I-iodine-labeled fibroblast growth factor-2 45 min after retroinfusion into the anterior cardiac vein (hashed bars, n = 3) or antegrade application into the left anterior descending artery (LAD) (black bars, n = 3). CX = circumflex artery.

performed using Mann-Whitney test. A p value <0.05 was considered statistically significant.

RESULTS

Implantation of the reduction stent resulted in a calculated degree of stenosis of about 75%. In the seven pigs used to establish the reduction-stent model, the angiographically determined degree of stenosis was 72 ± 3% and progressed to 91 ± 3% after seven days. After 28 days, the LAD was totally occluded in all pigs (Fig. 1C). Seven days after implantation of the reduction stent, regional myocardial blood flow at rest and adenosine-induced flow reserve were significantly decreased in the dependent LAD territory (Fig. 2A).

Twenty-eight days after implantation of the reduction stent, the decrease in regional myocardial blood flow at rest was even more pronounced (Fig. 2B), with a mean of 0.65 ± 0.1 ml·min⁻¹·g⁻¹ vs. 1.41 ± 0.15 ml·min⁻¹·g⁻¹ in

the CX territory. ¹³N-labeled ammonia- and ¹⁸FDG-PET was performed in three pigs of the control group and confirmed the presence of under-perfused but viable myocardium in the LAD territory at 28 days (Fig. 3). Infarct size determined by tetrazolium staining at 28 days (n = 7) was 2.0 ± 0.4% of the LV mass. Before treatment at day seven, groups A, B, and C were similar with regard to the degree of LAD stenosis (91 ± 3% vs. 92 ± 2% vs. 92 ± 2%, respectively) and systemic hemodynamics (Table 1).

Tissue binding of [¹²⁵I]FGF-2. To compare tissue binding of [¹²⁵I]FGF-2 after antegrade and retrograde delivery, radioactivity was determined in myocardial samples harvested 45 min after application at day seven in six pigs. After antegrade application, calculated FGF-2 retained in the targeted LAD territory was about 4.5 ± 1% (n = 3). After selective pressure-regulated retroinfusion, binding of FGF-2 in the targeted LAD territory was increased twofold to about 11 ± 2% (n = 3) (Fig. 4); thus, binding of [¹²⁵I]FGF-2 was increased 15- to 30-fold in the LAD territory compared with in the CX territory. After retrograde administration, FGF-2 binding was significantly lower in the lung (8,954 ± 1,860 vs. 128,140 ± 2,509 cpm/g, p < 0.05) but was not statistically different in the liver (84,148 ± 3,813 vs. 105,684 ± 27,521 cpm/g) and in the spleen (54,276 ± 6,059 vs. 82,716 ± 27,497 cpm/g).

Collateral score and capillary density. At day 28, the number of visible collateral arteries at postmortem angiography was higher in the retroinfusion group B (5.0 ± 1.3; p < 0.05) compared with the control group A (2.95 ± 0.4) and with the antegrade group C (3.3 ± 0.3). Similar results were obtained with regard to capillary density (capillaries/muscle fiber) being higher in group B (1.45 ± 0.2; p < 0.05) than in group A (1.0 ± 0.17) and group C (1.05 ± 0.15).

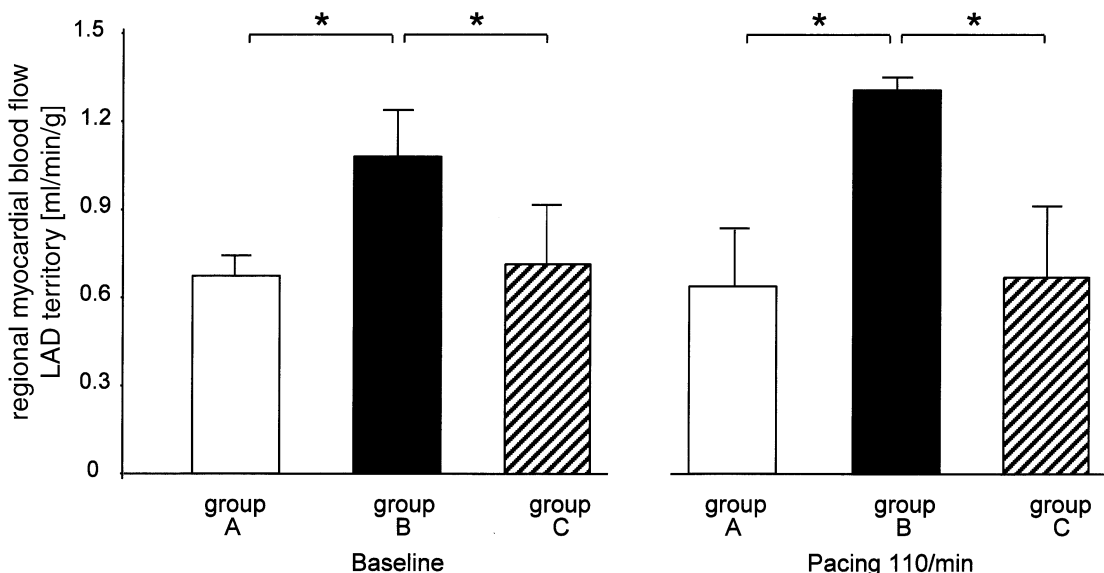


Figure 5. Regional transmural myocardial blood flow at day 28 in the left anterior descending artery (LAD) territory. Left panel = at rest; right panel = during pacing. Group A = controls; group B = retroinfusion of fibroblast growth factor-2; group C = antegrade delivery. *p < 0.05.

Table 2. Regional Myocardial Blood Flow

	Group A	Group B	Group C
LAD prox			
Epimyocardial	0.82 ± 0.11	1.35 ± 0.14*	1.06 ± 0.20
Midmyocardial	0.67 ± 0.08	1.28 ± 0.13*	0.72 ± 0.11
Endomyocardial	0.61 ± 0.09	1.23 ± 0.15*	0.65 ± 0.23
LAD dist			
Epimyocardial	0.70 ± 0.04	0.82 ± 0.13*	0.60 ± 0.18
Midmyocardial	0.59 ± 0.08	0.96 ± 0.13*	0.68 ± 0.14
Endomyocardial	0.55 ± 0.04	0.69 ± 0.15*	0.59 ± 0.14
CX			
Epimyocardial	1.46 ± 0.08	1.49 ± 0.11	1.47 ± 0.13
Midmyocardial	1.32 ± 0.11	1.36 ± 0.10	1.41 ± 0.12
Endomyocardial	1.21 ± 0.06	1.21 ± 0.13	1.27 ± 0.15

Regional myocardial blood flow [ml/min/g]: group A (controls), group B (retroinfusion of fibroblast growth factor-2) group C (antegrade infusion of fibroblast growth factor-2); mean ± SEM, n = 7/group, *p < 0.05 vs. control (group A).

CX = circumflex artery; dist = distal; LAD = left anterior descending artery; prox = proximal.

Regional myocardial blood flow. At day 28, regional myocardial blood flow at rest in the LAD territory was significantly higher in pigs treated with retroinfusion of FGF-2 (group B) than in group A and in group C (Fig. 5): $1.07 \pm 0.14 \text{ ml}\cdot\text{min}^{-1}\cdot\text{g}^{-1}$ vs. $0.66 \pm 0.07 \text{ ml}\cdot\text{min}^{-1}\cdot\text{g}^{-1}$, vs. $0.72 \pm 0.17 \text{ ml}\cdot\text{min}^{-1}\cdot\text{g}^{-1}$. Of note, regional myocardial blood flow in the ischemic LAD territory was significantly lower than in the CX territory in all groups (Table 2). There was a gradient from proximal to distal probes and from the epicardial to the endocardial layers

within the LAD territory in all groups (Table 2). In pigs treated by retroinfusion of FGF-2 (group B), this difference was significant between the proximal and distal endocardial probes (1.23 ± 0.15 vs. $0.69 \pm 0.15 \text{ ml}\cdot\text{min}^{-1}\cdot\text{g}^{-1}$). Under the condition of increased oxygen demand during pacing (110 beats/min), regional myocardial blood flow in the LAD territory slightly increased in pigs of group B (retroinfusion of FGF-2) but was unchanged in group A and group C (Fig. 5).

Regional myocardial function. The impact of FGF-2 treatment at day seven on regional myocardial function at day 28 was studied at rest and during pacing. Substantial preservation of regional myocardial function at day 28 was observed within the LAD territory after retroinfusion of FGF-2 at day seven in group B (Fig. 6). The efficacy, however, decreased with the distance to the reduction stent. In the proximal ischemic LAD territory (1 cm distal to the reduction stent), subendocardial segment shortening was well preserved in the retroinfusion group B ($18.5 \pm 4.1\%$ [% end-diastolic length]) in contrast to controls ($5.7 \pm 2.9\%$) (Fig. 6, top panel). Similar results were obtained with regard to pacing induced functional reserve. In the distal LAD territory, regional myocardial function at rest was compromised in all groups (Fig. 6, bottom panel). During pacing, dyskinesia developed in groups A and C, in contrast to group B (Fig. 6, bottom panel).

Global LV function. Global LV function was similar at day seven in all groups (Table 1). Twenty-one days after

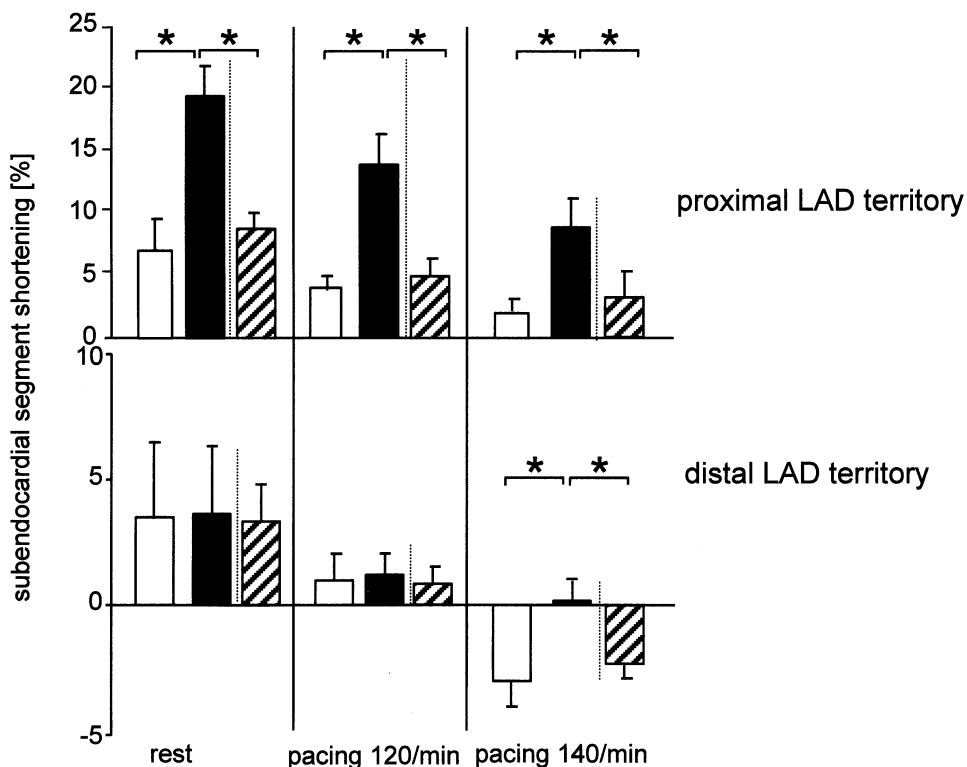


Figure 6. Regional myocardial function at day 28. **White bars** (group A) = controls; **black bars** (group B) = retroinfusion of fibroblast growth factor-2; **hashed bars** (group C) = antegrade delivery. **Top panel** = proximal ischemic left anterior descending artery (LAD) territory; **bottom panel** = distal ischemic LAD territory.

treatment, however, LVEDP increased in the control group A (16.5 ± 2.1 mm Hg) and was significantly higher than in the retroinfusion group B (10.8 ± 1.6 mm Hg). Antegrade infusion of FGF-2 (group C) was also associated with higher LV end-diastolic pressure (14.3 ± 1.5 mm Hg), though less pronounced than in controls.

Infarct size. At day 28 after implantation of the reduction stent, the extent of MI was not different in groups A, B, and C determined by morphometric and histological assessment. In nine representative probes of the LAD territory assessed from each pig, transmural necrosis was found in 0.9 ± 0.2 probes of group A, 1.0 ± 0.2 probes of group B, and 0.8 ± 0.2 probes of group C. Focal necrosis was seen in 1.9 ± 0.3 probes of group A, 1.9 ± 0.4 probes of group B, and 1.9 ± 0.3 probes of group C.

DISCUSSION

Chronic myocardial ischemia induced by implantation of a reduction stent. A novel catheter-based approach was used in this study instead of surgical placement of an ameroid constrictor (5,19) for induction of chronic myocardial ischemia. Using a percutaneously implanted reduction stent, a highly reproducible degree of LAD stenosis was achieved acutely and the degree of stenosis increased from about 72% to about 91% at seven days. Thus, regional myocardial blood flow in the LAD territory was moderately reduced at rest and flow reserve was significantly reduced (Fig. 2A). Adenosine stress was used to assess flow reserve and to compare it with the data known from the well-established ameroid constrictor model (5,19,20). Similar to the ameroid constrictor model, the time point of complete occlusion of the coronary artery was not exactly defined after implantation of the reduction stent. As the patency of the stents at seven days was a prerequisite for the inclusion in the treatment groups, total occlusion of the reduction stent occurred between day seven and day 28 (Fig. 1C).

The extent of MI at day 28 in controls was similar to the ameroid constrictor model applied in the CX in the pig (20). In contrast to the ameroid constrictor model (21,22), myocardial blood flow at rest was significantly reduced in controls at day 28 (Fig. 2B). Accordingly, regional myocardial function at rest was also impaired in the LAD territory, in line with the definition of hibernating myocardium and in agreement with the findings in a pig model of chronically hibernating myocardium (23,24). The presence of hibernating myocardium at day 28 was also confirmed in an exemplary fashion by the increased FDG uptake in the under-perfused LAD territory (Fig. 3).

Angiogenic effects induced by selective pressure-regulated retroinfusion of FGF-2. Selective pressure-regulated retroinfusion into the coronary veins was used for the first time to deliver recombinant angiogenic growth factors into ischemic myocardium, in line with the concept of prolonging contact time of drugs and gene vectors (12-14). After retroinfusion of FGF-2 (day seven), the number of collateral arteries visible at postmortem angiog-

raphy (day 28) was significantly increased compared with in controls and with antegrade delivery. Although collateral blood flow in pigs is very low in acute ischemia (25), the development of collateral arteries has been described in case of severe chronic ischemia (19,26). Hence, the development of angiographically visible collateral arteries was enhanced after retroinfusion of FGF-2.

Histology also showed increased capillary density in the LAD territory 21 days after retroinfusion of FGF-2. Furthermore, short-term treatment (30 min) by retroinfusion of FGF-2 clearly enhanced tissue binding compared with antegrade delivery (Fig. 4). About 5% of the applied radioactivity was detected in the LAD territory after antegrade delivery of [125 I]FGF-2, similar to results obtained in a dog model (26). Retroinfusion resulted in an about twofold increase in tissue binding of FGF-2 compared with antegrade delivery, indicating successful targeting of FGF-2 to the ischemic myocardium. Because tissue binding of FGF-2 was determined only once in our study (45 min after application), we cannot exclude different redistribution kinetics with both modes of delivery.

Selective retroinfusion led to a 15- to 30-fold increase in tissue binding of [125 I]FGF-2 in the targeted ischemic LAD territory compared with in the non-ischemic CX territory. Nevertheless, systemic redistribution was present with both delivery methods, especially to the lungs, the liver, and the spleen. However, there were no abnormal macroscopic or histologic findings, such as hemangioma formation, in adjacent or remote organs.

Effects on regional myocardial blood flow and function.

The impact of arteriogenesis and angiogenesis on regional myocardial blood flow and function was determined 21 days after treatment. Of note, regional myocardial blood flow was reduced under resting conditions in all three groups, indicating the presence of ischemia in the LAD territory (Fig. 5). The level of regional myocardial ischemia in the LAD territory, however, was different in the three groups. This difference was not explained by an imbalance in the extent of MI between the three groups, which was ruled out by morphometric and histological determination.

As expected from the increase in collaterals and the density of capillaries, regional myocardial blood flow at rest was higher in pigs treated by retroinfusion of FGF-2. Improved regional myocardial blood flow in the LAD territory of pigs treated by retroinfusion of FGF-2 was accompanied by a significant preservation of regional myocardial function, as segment shortening in the proximal LAD territory was substantially higher at rest and during increased oxygen demand. Increased oxygen demand by atrial pacing was used instead of adenosine-induced flow reserve to detect functional relevant recovery of hibernating myocardium. Thus, for the distal LAD territory, differences in segment shortening between the groups were detected during pacing, showing that regional dyskinesia was prevented only after retroinfusion of FGF-2 (Fig. 6). In contrast to the proximal LAD

territory, the preservation of regional myocardial blood flow in the distal LAD territory was not sufficient to prevent myocardial dysfunction at rest, which is reasonable for a decrease in subendocardial blood flow to $0.69 \pm 0.15 \text{ ml}\cdot\text{min}^{-1}\cdot\text{g}^{-1}$ in pigs (27).

Although there was a trend toward improved regional myocardial blood flow and function in pigs treated by antegrade infusion, this effect did not reach statistical significance, which is in agreement with observations in dogs after single antegrade injection of FGF-2 (3). A limitation of the present study, however, is that treatment groups were not randomly assigned.

Conclusions. We characterized a new pig model with percutaneous induction of chronic myocardial ischemia and with preliminary data indicating the development of hibernating myocardium in the LAD territory. As catheter-based access to the cardiac veins is not hampered, this model is suitable for studying the effects of angiogenic proteins, such as FGF-2 by retrograde delivery into the cardiac veins. Selective pressure-regulated retroinfusion of FGF-2 significantly improved regional perfusion and function, suggesting that retrograde FGF-2 delivery increased tissue binding and targeted FGF-2 to vessel segments most receptive and responsive to them (28,29). The preservation of regional myocardial blood flow and function, however, was still incomplete after the short-term (30 min) retrograde treatment. Whether higher concentrations of FGF-2 or longer retroinfusion periods might enhance the efficacy has not been addressed in this study. Furthermore, the combined application of FGF-2 with other angiogenic proteins might be a promising approach based on reports of their synergistic effects (18,30).

Reprint requests and correspondence: Prof. Dr. med. Peter Boekstegers, Medizinische Klinik I, Klinikum Grosshadern, Marchioninistr. 15, D-81377 München, Germany. E-mail: boekstegers@med1.med.uni-muenchen.de.

REFERENCES

1. Kornowski R, Fuchs S, Leon MB, et al. Delivery strategies to achieve therapeutic myocardial angiogenesis. *Circulation* 2000;101:454-8.
2. Schumacher B, Pecher P, Von Specht BU, et al. Induction of neoangiogenesis in ischemic myocardium by human growth factors: first clinical results of a new treatment of coronary heart disease. *Circulation* 1998;97:645-50.
3. Rajanayagam MA, Shou M, Thirumurti V, et al. Intracoronary basic fibroblast growth factor enhances myocardial collateral perfusion in dogs. *J Am Coll Cardiol* 2000;35:519-26.
4. Sato K, Wu T, Laham RJ, et al. Efficacy of intracoronary versus intravenous FGF-2 in a pig model of chronic myocardial ischemia. *Ann Thorac Surg* 2000;70:2113-8.
5. Unger EF, Banai S, Shou M, et al. A model to assess interventions to improve collateral blood flow: continuous administration of agents into the left coronary artery in dogs. *Cardiovasc Res* 1993;27:785-91.
6. Battler A, Scheinowitz M, Hasdai D, et al. Intracoronary injection of basic fibroblast growth factor enhances angiogenesis in infarcted swine myocardium. *J Am Coll Cardiol* 1993;22:2001-6.
7. Lopez JJ, Laham RJ, Stamler A, et al. VEGF administration in chronic myocardial ischemia in pigs. *Cardiovasc Res* 1998;40:272-81.
8. Henry TD, McKendall GR, Azrin MA, et al. VIVA Trial: one year follow up. *Circulation* 2000;102:II309.
9. Kleiman NS, Califf RM. Results from late-breaking clinical trials sessions at ACCIS 2000 and ACC 2000. American College of Cardiology. *J Am Coll Cardiol* 2000;36:310-25.
10. Freedman SB, Isner JM. Therapeutic angiogenesis for coronary artery disease. *Ann Intern Med* 2002;136:54-71.
11. Boekstegers P, Giehl W, von Degenfeld G, et al. Selective suction and pressure-regulated retroinfusion: an effective and safe approach to retrograde protection against myocardial ischemia in patients undergoing normal and high risk percutaneous transluminal coronary angioplasty. *J Am Coll Cardiol* 1998;31:1525-33.
12. Boekstegers P, von Degenfeld G, Giehl W, et al. Myocardial gene transfer by selective pressure-regulated retroinfusion of coronary veins. *Gene Ther* 2000;7:232-40.
13. von Degenfeld G, Giehl W, Boekstegers P, et al. Targeting of dobutamine to ischemic myocardium without systemic effects by selective suction and pressure-regulated retroinfusion. *Cardiovasc Res* 1997;35:233-40.
14. Kupatt C, Wichels R, Deiss M, et al. Retroinfusion of NFkappaB decoy oligonucleotide extends cardioprotection achieved by CD18 inhibition in a preclinical study of myocardial ischemia and retroinfusion in pigs. *Gene Ther* 2002;9:518-26.
15. Waltenberger J, Usuki K, Fellström B, Funai K, Heldin CH. Platelet-derived endothelial cell growth factor: pharmacokinetics, organ distribution and degradation after intravenous administration in rats. *FEBS Lett* 1992;313:129-32.
16. Raab S, Thein E, Harris AG, et al. A new sample-processing unit for the fluorescent microsphere method. *Am J Physiol* 1999;276:H1801-6.
17. Boekstegers P, Peter W, von Degenfeld G, et al. Preservation of regional myocardial function and myocardial oxygen tension during acute ischemia in pigs: comparison of selective synchronized suction and retroinfusion of coronary veins to synchronized coronary venous retroperfusion. *J Am Coll Cardiol* 1994;23:459-69.
18. Asahara T, Bauters C, Zheng LP, et al. Synergistic effect of vascular endothelial growth factor and basic fibroblast growth factor on angiogenesis in vivo. *Circulation* 1995;92:II365-71.
19. Mack CA, Patel SR, Schwarz EA, et al. Biologic bypass. *J Thorac Cardiovasc Surg* 1998;115:168-76.
20. Harada K, Grossman W, Friedman M, et al. Basic fibroblast growth factor improves myocardial function in chronically ischemic porcine hearts. *J Clin Invest* 1994;94:623-30.
21. Lopez JJ, Laham RJ, Stamler A, et al. VEGF administration in chronic myocardial ischemia in pigs. *Cardiovasc Res* 1998;40:272-81.
22. Hariawala MD, Horowitz JR, Esakof D, et al. VEGF improves myocardial blood flow but produces EDRF-mediated hypotension in porcine hearts. *J Surg Res* 1996;63:77-82.
23. Rahimtoola SH. The hibernating myocardium. *Am Heart J* 1989;118:211-22.
24. Fallavollita JA, Logue M, Cauty JM. Stability of hibernating myocardium in pigs with a chronic left anterior descending coronary artery stenosis: absence of progressive fibrosis in the setting of stable reductions in flow, function and coronary flow reserve. *J Am Coll Cardiol* 2001;37:1989-95.
25. White FC, Carroll SM, Magnet A, et al. Coronary collateral development in swine after coronary artery occlusion. *Circ Res* 1992;71:1490-500.
26. Lazarous DF, Shou M, Stiber JA, et al. Pharmacodynamics of basic fibroblast growth factor: route of administration determines myocardial and systemic distribution. *Cardiovasc Res* 1997;36:78-85.
27. Conzen PF, Habazettl H, Christ M, et al. Left ventricular surface tissue oxygen pressures determined by oxygen sensitive multiwire electrodes in pigs. *Cardiovasc Res* 1991;25:207-16.
28. Bategay EJ. Angiogenesis: mechanistic insights, neovascular diseases, and therapeutic prospects. *J Mol Med* 1995;73:333-46.
29. Folkman J, Shing Y. Angiogenesis. *J Biol Chem* 1992;267:10931-4.
30. Pepper MS, Ferrara N, Orci L, et al. Potent synergism between vascular endothelial growth factor and basic fibroblast growth factor in the induction of angiogenesis in vitro. *Biochem Biophys Res Commun* 1992;189:824-31.